

## Endocrine:

### 1. Pituitary gland:

Anterior lobe AKA \_\_\_\_\_

- Develops from the \_\_\_\_\_ pouch

#### 1. Somatotrophs produce Growth Hormone (GH)

- Too much GH in children =

- Too much GH in adults =

Increased GH, Increased insulin resistance → DM

Laron syndrome (Dwarfism)

- Defective GH **receptors**

- Increased GH, Decreased IGF

#### 2. Lactotrophs produce Prolactin (PRL)

- Prolactinoma: Treat with dopamine **agonist**

#### 3. Mammotrophs produce GH and PRL

4. Corticotrophs produce Pro-opiomelanocortin (POMC) [**cleaved** into Adrenocorticotrophic Hormone (ACTH) and Melanocyte Stimulating Hormone (MSH), Endorphin]

- Cushing syndrome vs. Cushing disease?

- What are characteristics of Cushing syndrome?

#### 5. Thyrotrophs produce Thyroid Stimulating Hormone (TSH)

#### 6. Gonadotrophs produce Follicle-Stimulating Hormone (FSH) and Luteinizing Hormone (LH)

- Primary hypothalamic control of **prolactin by dopamine** is + or -?

- What is unique about the control of growth hormone?

- What is the difference between a functioning and non-functioning pituitary adenoma?

Pituitary adenomas: Typically sporadic G protein mutations

**Sheehan syndrome!!**

Pituitary Cell Type	Hormone	Associated Syndrome
Lactotroph	Prolactin	Galactorrhea and amenorrhea, sexual dysfunction, infertility, osteoporosis
Somatotroph	GH	Gigantism (children) Acromegaly (adults)
Corticotroph	ACTH and other POMC-derived peptides	Cushing syndrome Nelson syndrome
Mammotroph	Prolactin, GH	Combined features of GH and prolactin excess
Thyrotroph	TSH	Hyperthyroidism

Posterior lobe AKA \_\_\_\_\_

- Downward projection of brain

#### 1. Oxytocin: stimulates uterine contraction during labor and milk ejection

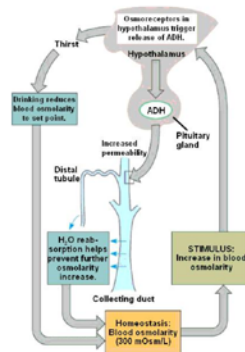
2. Antidiuretic hormone (ADH, vasopressin): Water retention by renal collecting ducts by restricting diuresis during dehydration or hypovolemia

1. Diabetes Insipidus: Low ADH → Polyuria / Polydipsia

2. Syndrome of Inappropriate ADH: High ADH → Hyponatremia

## Posterior Pituitary Pathology Diabetes Insipidus

- Low ADH secondary to head trauma, surgery, tumors, and inflammatory disorders of the hypothalamus and pituitary
  - Central DI: ADH deficiency
  - Nephrogenic DI: unresponsiveness by renal tubules to ADH
  - Iatrogenic DI: Lithium, demeclocycline



Other:

1. Rathke cleft cyst
  - Rathke's pouch, embryonic structure arising in the roof of the mouth and forms the anterior pituitary gland
  - Remnants can accumulate fluid, become cystic, expand
2. Empty sella syndrome
  - Rare condition due to malformation of sella turcica that becomes filled with CSF
3. Craniopharyngioma
  - Derived from remnants of Rathke pouch
  - Growth retardation (pituitary hypofunction and GH deficiency) in children
    - Children: adamantinomatous craniopharyngioma
  - Headaches and visual disturbances common presentation in adults
    - Adults: papillary craniopharyngioma
4. Pituitary carcinoma
  - Can be hormone producing prolactin and ACTH

### Neuroendocrine Tumors:

1. Small Cell Carcinoma (Neuroendocrine Neoplasm of the Lung)
  - Smokers
  - Paraneoplastic syndromes, tumor may produce:
    - ADH (causing SIADH), ACTH (Cushing syndrome)
    - Antibodies against presynaptic calcium channels (Lambert Eaton syndrome)
    - Antibodies against neurons/neuromuscular junction
2. Carcinoid Tumors (Neuroendocrine Neoplasm of the Lung)
  - **Chromogranin A and Synaptophysin** are Immunohistochemical stains positive in most carcinoid tumors
  - Carcinoid syndrome (intermittent diarrhea, flushing, asthmatic wheezing, right-sided valvular heart disease (tricuspid regurgitation, pulmonic stenosis) due to lung Monoamine oxidase-A (MAO-A) enzymatic breakdown of serotonin (5-HT; 5-hydroxytryptamine)
  - 1/3 metastasize, 1/3 Present with second malignancy, 1/3 are multiple
3. Well Differentiated NETs (Carcinoid Tumors) of GI Tract
  - Most common malignancy in small intestine
  - No carcinoid syndrome

Most common prognostic factor for GI carcinoid tumors is location

- Foregut NETs (esophagus, stomach, proximal duodenum) most rarely metastasize and are generally cured by resection
- Midgut NETs (jejunum and ileum) are often multiple and tend to be aggressive
- Hindgut NETs (appendix-almost always benign), (colorectal-variable behavior; when symptomatic, present with abdominal pain and weight loss)

#### 4. Gastric NETs

##### Zollinger Ellison syndrome-

- Caused by gastrin secreting tumor (gastrinoma) of duodenum or pancreas
- Can cause **Type 2 ECL-like NET** in the stomach
- Acid hypersecretion causes recurrent ulcers in duodenum and jejunum
- Patient presents with abdominal pain (peptic ulcer disease, duodenal ulcers) or chronic diarrhea (malabsorption)
- Thickened mucosal folds due to increased parietal cells
- Positive secretin stimulation test: gastrin levels remain elevated after administration of secretin, which normally inhibits gastrin release 21

**Gastrinomas lead to Zollinger-Ellison syndrome**

	Type 1 ECL-like NET	Type 2 ECL-like NET
Frequency	80-90%	5-7%
Hypergastrinemia	Yes	Yes
Background mucosa	Atrophic gastritis Often autoimmune, with anti-parietal cell or anti-intrinsic factor antibodies	Parietal cell hypertrophy/hyperplasia; Associated with hypergastrinemia due to gastrinomas in duodenal or pancreas (associated with Zollinger-Ellison synd) Also assoc with MEN I
Acid secretion	Low or absent	High
Metastasis rate	1-3%	10-30%
5 year survival rate	almost 100%	60-90%

#### 5. Appendiceal NET

- Pathogenesis of appendiceal neoplasms is largely unknown
- Well-differentiated NET (carcinoid) is most common tumor of the appendix; benign
- 80% of appendiceal NETs found incidentally after surgery for acute appendicitis, usually at tip of appendix

#### 6. Pancreatic Neuroendocrine Neoplasms

- Represent 1-2% of all pancreatic neoplasms, majority of pancreatic neoplasms occur in the exocrine pancreas
- Occur at any age but are rare in childhood (usually age 40 –60)
- Exhibit variable biologic behavior (benign or malignant). Malignant forms are defined by presence of metastases, vascular invasion, and local infiltration
- May produce hormones or be non-functional. Type of hormone produced has prognostic implications:

Up to 90% of other functioning and nonfunctioning tumors are malignant

- **Most are non-functioning**

##### 1. Insulinoma

- **90% of insulinomas are benign (most common)**

Whipple triad:

- Low blood glucose
- Symptoms of hypoglycemia (lethargy, syncope, diplopia)

– Resolution of symptoms after normalization of glucose levels

## 2. Gastrinoma

**Gastrinoma: Second most common functioning pancreatic neuroendocrine tumor**

- Gastrin secretion
- Most sporadic, 1/3 familial
- Malignant in 60-90% (spread to lymph nodes at time of diagnosis)
- **"Gastrinoma triangle" (common bile duct, duodenum, pancreatic head)**  
- 90% of gastrinomas lie here

## 3. Glucagonoma

- Tumor of pancreatic  $\alpha$ -cells, have overproduction of glucagon
- D's: Diabetes (hyperglycemia), Dermatitis (necrolytic migratory erythema), Deep vein thrombosis, Depression, Declining weight

## 4. VIPoma: Vasoactive intestinal peptide secreting NET

- Uncontrolled secretion of VIP causes Verner-Morrison syndrome (pancreatic cholera)(**WDHA** syndrome): **W**atery **D**iarrhea (usually >1 L of stool per day), **H**ypokalemia, **A**chlorhydria / hypochlorhydria

## 5. Somatostatinoma:

Tumor of pancreatic  $\delta$  cells, overproduction of somatostatin, causes decreased secretion of secretin, cholecystokinin, glucagon, insulin, gastrin, gastric inhibitory peptide

## 7. Pheochromocytoma

- Hypertension usually paroxysmal (episodic, relapse and remit)
- Pressure (increased BP), Pain (headache), Perspiration, Palpitations (tachycardia), Pallor
- Results from hyperproduction of catecholamines (epinephrine and norepinephrine); May also secrete erythropoietin causing polycythemia
- Increased urinary excretion of catecholamines and their metabolites (metanephrine, normetanephrine, vanillylmandelic acid)
- Can be part of MEN IIA or MEN IIB (III)

## 8. Neuroblastoma

- Highly malignant catecholamine-producing tumor
- Occurs in early childhood
- Urinary catecholamines and catecholamine metabolites are same as in pheochromocytoma
- Tumor causes hypertension
- Usually originates in adrenal medulla
- Often presents as large abdominal mass

Malignant "small blue cell" tumor of adrenal medulla

## 9. MEN Syndromes

### 1. Type 1: Wermer Syndrome

It affects the parathyroid, pituitary and pancreas (3Ps):

- Parathyroid: Majority of the patients present with primary hyperparathyroidism caused by hyperplasia and/or adenomas
- Pancreas: Endocrine pancreatic tumors are the major cause of morbidity and mortality in patients with MEN 1. Multiple tumors are common with dominant lesions showing aggressive behavior and metastasis. Gastrinomas (Zollinger-Ellison syndrome) and insulinomas are most common; also VIPomas, glucagonomas
- Pituitary: Prolactin and GH adenomas are most common

### 2. Type 2

- MEN2 A or Sipple Syndrome
  - Familial Medullary Thyroid Cancer
- MEN2B

Medullary Thyroid Carcinoma	Multiple and aggressive
Pheochromocytomas	
Mucosal Neuromas/Ganglioneuromas	Skin, oral mucosa, eyes, respiratory and GI tracts
Marfanoid habitus	Long axial skeletal features and hyperextensible joints

## Adrenal

### I. Normal Anatomy and Histology

### II. Adrenal cortex

#### A. Hyperfunction - **Increased** cortisol production

##### 1. Cortisol (ACTH dependant vs independent) – Cushing SYNDROME

###### A. ACTH dependant

- Pituitary hyperfunction (usually tumor) = Cushing DISEASE
- Ectopic ACTH from a tumor

###### B. ACTH independent

- Functional adrenal neoplasm (adenoma vs carcinoma)
- Hyperplasia
  - Macronodular hyperplasia
  - Primary pigmented nodular adrenal disease

##### 2. Aldosterone (Conn syndrome)

##### 3. Androgens (Congenital adrenal hyperplasia)

###### A. Congenital adrenal hyperplasia

- Intrinsic defect in production of cortisol
- Precursors shunted towards production of adrenal androgens
- Increase in ACTH
- Often presents with ambiguous genitalia and adrenal hyperplasia in neonates

###### B. Tumor

### B. Tumors

#### 1. Adrenocortical adenoma

May be functional or not functional

- Atrophy of adrenal cortex may indicate functional status
- “Spironalactone bodies” in patients treated with the drug

- Adenoma vs carcinoma largely based on size and invasion of adjacent structures, both typically yellow

- Microscopic: Similar to normal adrenal cortex,

- 1) polygonal cells
- 2) clear/vacuolated cytoplasm
- 3) growing in sheets

#### 2. Adrenocortical carcinoma

### C. Hypofunction - **Decreased** cortisol production

#### A. Acute adrenal insufficiency

- Iatrogenic (rapid withdrawal of steroids)
- Waterhouse Friderichsen syndrome
  - Hemorrhage and necrosis of adrenal gland secondary to sepsis (classically Neisseria)
  - Associated with DIC

#### B. Chronic adrenal insufficiency (**Addison's disease**)

- Most cases are due to autoimmune disease (80-90%)
- Infection (TB, HIV associated infections)
- Metastatic tumor destroying adrenal gland
- Clinical symptoms
  - Weakness, GI symptoms, hypoglycemia (cortisol)
  - Hyperkalemia, hyponatremia (aldosterone)
  - Hyperpigmentation (elevated ACTH, POMC)

#### C. Secondary adrenocortical insufficiency

- Due to hypothalamic or pituitary dysfunction
- Atrophic adrenal glands
- No hyperpigmentation

### III. Adrenal medulla

#### A. Tumor

##### A. Pheochromocytoma

- Tumor of the adrenal medulla
- One of the most hereditary tumors in the human body (MEN, NF1, VHL, SDHx)
- Rule of 10's
- 10% malignant, bilateral, extra-adrenal (paraganglioma)
- Sx: hypertension, anxiety, palpitations, sx may be transient
- Can detect elevated catecholamines and other metabolites (dopamine, VMA, metanephrine) in blood and serum
- Path: Classically, BASOPHILIC and GRANULAR with a syncytial growth pattern and prominent vasculature
- Difficult to tell malignant from benign

##### B. Neuroblastoma

##### C. MEN

Group of genetic diseases predisposing to endocrine neoplasms in multiple sites

##### ■MEN I

- Pituitary adenoma, parathyroid adenoma/hyperplasia, pancreatic islet cell tumor (3 P's)
- MEN1 mutation

##### ■MEN 2A

- Pheochromocytoma, Medullary thyroid carcinoma, parathyroid hyperplasia
- RET mutation

##### ■MEN 2B

- Pheochromocytoma, Medullary thyroid, mucocutaneous ganglioneuromas
- RET mutation

## Diabetes Mellitus:

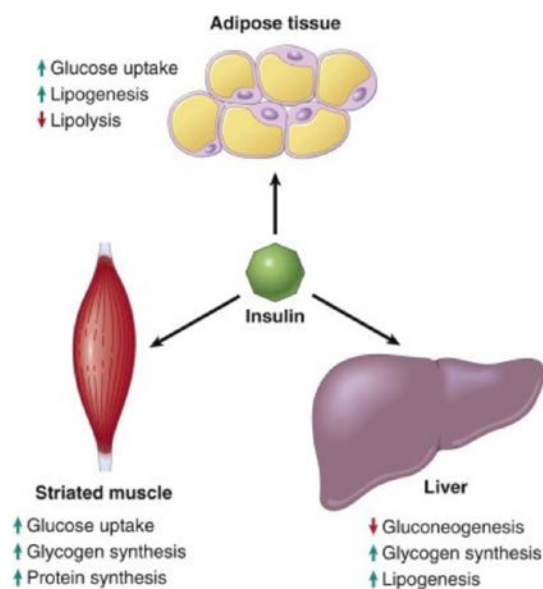
### Fast facts:

C peptide released when proinsulin is converted to insulin

–C peptide levels can be measured and used to determine if a patient has taken **exogenous insulin**

### Insulin effects - ANABOLIC

- Decreases blood glucose levels
  - Promotes glucose transport into cells (muscle and liver)
  - Promotes glycogen production (liver)
  - Inhibits gluconeogenesis (liver)
- Decrease blood fatty acid levels
- Decrease blood amino acid levels



### Glucagon effects - CATABOLIC

- Increases blood glucose levels
  - Decreases glucose transport into cells (liver)
  - Inhibits glycogen production (liver)
  - Promotes gluconeogenesis (liver)
- Increase blood fatty acid levels
- Decrease blood amino acid levels (converted to glucose)

### Type 1 DM

- Autoimmune disease
- T cell mediated destruction of beta cells
- Younger patients
- Normal weight
- Relatively uncommon (5-10% of cases)

### Type 2 DM

- Insulin resistance and beta cell dysfunction
- Some patients may have genetic predisposition
- Older patients (usually)
- Often obese
- Very common (95% of cases)

Insulin resistance leads to beta cell dysfunction/death and hyperglycemia

- Decreased insulin consequences
  - Failure to inhibit gluconeogenesis
  - Failure of glucose uptake in liver and muscle
  - Failure of inhibition of lipolysis

### HYPERGLYCEMIA

Basement membrane thickening – Vascular damage

Small vessels: Arteriosclerosis and vascular damage (THICK BUT WEAK) - MICRO

- Retinopathy
  - #1 cause of adult onset blindness
- Nephropathy
  - #1 cause of renal failure
- Peripheral neuropathy

## Big picture: Solid pancreatic tumors

- Pancreatic adenocarcinoma
  - Derived from pancreatic ducts
  - Most common pancreatic tumor
  - Very bad prognosis
- Pancreatic neuroendocrine tumor
  - Derived from neuroendocrine cells in the islets of Langerhans
  - Not very common (5% of pancreatic neoplasms)
  - Better prognosis but still often fatal
- Pancreatic acinar cell carcinoma
  - Derived from pancreatic acinar tissue
  - Extremely rare (you'll probably never see one)
  - Bad prognosis

### Thyroid:

#### Hyperthyroidism:

- Grave's – Scalloped borders, IgG autoantibodies bind to TSH receptor stimulating hormone production

Primary
Graves disease
Hyperfunctional multinodular goiter
Hyperfunctional adenoma of the thyroid
Secondary
TSH-secreting pituitary adenoma

### **Hypothyroidism:**

- Hashimoto's
- Cretinism: Impaired neural and skeletal development in infancy/ childhood

Primary
Iodine Deficiency
Autoimmune → Hashimoto's Thyroiditis
Developmental/ Congenital
Iatrogenic (drugs/surgical tx)
Secondary
Pituitary/ Hypothalamic failure

### **Neoplasms:**

- Follicular Adenoma
- Papillary Carcinoma – Most common form of thyroid cancer
- Follicular Carcinoma
- Anaplastic (Undifferentiated) Carcinoma
- Medullary Carcinoma
- **Primary Hyperparathyroidism**

#### Clinical Features

Most often asymptomatic hypercalcemia

Manifestations are due to high PTH and Ca<sup>++</sup> levels:

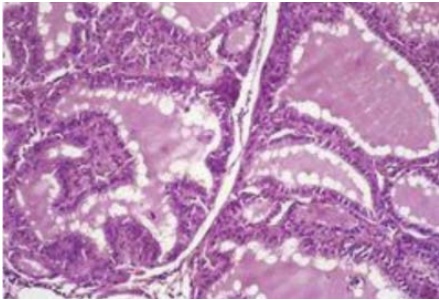
"PAINFUL BONES, RENAL STONES, ABDOMINAL GROANS, AND PSYCHIC MOANS"

1. Nephrolithiasis: Formation of Ca<sup>++</sup> oxalate stones in 20% of patients can cause obstruction and renal insufficiency
2. Osteitis fibrosa cystica: Bone resorption causes cystic degeneration, fibrosis and osteoporosis
3. Constipation, peptic ulcers, gallstones and acute pancreatitis
4. CNS alterations including depression, lethargy and seizures
5. Neuromuscular abnormalities (weakness and fatigue)
6. Aortic /mitral valve calcifications

1. A 22-year-old woman has experienced increasing fatigue and a 7-kg weight loss without dieting over the past 4 months. She also has experienced increasing anxiety and nervousness with no apparent changes in her job or home life. She now has diarrhea. Physical examination shows a diffusely enlarged thyroid gland. Her temperature is 37.6°C, pulse is 103/min, respirations are 17/min, and blood pressure is 135/75 mm Hg. A radionuclide scan of the thyroid shows a diffuse increase in uptake. The figure

shows the representative microscopic appearance of the thyroid gland at high power. She is diagnosed with Grave's disease. What is most likely to produce these findings?

- (A) Antibodies against TSH receptor
- (B) Dietary deficiency of iodine
- (C) Mutation in the RET proto-oncogene
- (D) Maternal deficiency in T4
- (E) Irradiation of the neck



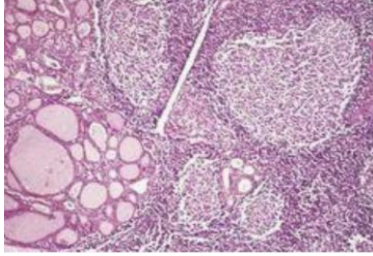
2. A 55-year-old man has experienced increasing lethargy for the past 7 months. Physical examination shows hyperpigmentation of the skin. Vital signs include temperature of 36.9°C, pulse of 70/min, respirations of 14/min, and blood pressure of 95/65 mm Hg. Laboratory studies include a serum cortisol level of 3 µg/mL at 8:00 am with a serum corticotropin level of 65 pg/mL. Which disease does he have?

- (A) Systemic lupus erythematosus
- (B) Hashimoto thyroiditis
- (C) Diabetes mellitus type 2
- (D) Addison's disease
- (E) Polyarteritis nodosa

3. A 25-year-old woman has noted breast secretions for the past month. She is not breastfeeding and has never been pregnant. She has not menstruated for the past 5 months. Physical examination yields no abnormal findings. MRI of the brain shows a 0.7-cm mass in the adenohypophysis. What is the diagnosis? Treatment?

4. A 46-year-old woman has experienced a feeling of fullness in her neck for the past year. Her energy level is decreased, and she has difficulty concentrating at work. On physical examination, the thyroid gland is enlarged diffusely and symmetrically and is not tender on palpation. She has dry, coarse skin and alopecia. The figure shows the microscopic appearance of the thyroid gland. Which of the following autoantibodies is most likely to be present in the serum of this patient?

- (A) Antithyroid peroxidase
- (B) Antimitochondrial
- (C) Antiribonucleoprotein
- (D) Anti-double-stranded DNA
- (E) Anti-gastric parietal cell
- (F) Anticentromere
- (G) Anti-Jo-1



5. An infant is born at term to a 25-year-old woman. On newborn physical examination, the infant is found to have an enlarged abdomen, but there are no other abnormal findings except for slightly elevated blood pressure. An abdominal ultrasound scan shows a right retroperitoneal mass in the adrenal gland. Diagnosis?

6. A 42-year-old man sees his physician because he has had polyuria and polydipsia for the past 4 months. His medical history shows that he fell off a ladder and hit his head just before the onset of these problems. On physical examination, there are no specific findings. Laboratory findings include serum Na<sup>+</sup>, 155 mmol/L; K<sup>+</sup>, 3.9 mmol/L; Cl<sup>-</sup>, 111 mmol/L; CO<sub>2</sub>, 27 mmol/L; glucose, 84 mg/dL; creatinine, 1 mg/dL; and osmolality, 350 mOsm/mL. The specific gravity of urine is 1.002. This patient is most likely to have a deficiency of which of the following hormones?

- (A) Oxytocin
- (B) Antidiuretic hormone
- (C) Corticotropin
- (D) Prolactin
- (E) Melatonin

7. A 37-year-old woman states that, although most of the time she feels fine, she has experienced episodes of palpitations, tachycardia, tremor, diaphoresis, and headache over the past 3 months. When her symptoms are worse, her blood pressure is in the range of 155/90 mm Hg. She collapses suddenly one day and is brought to the hospital, where her ventricular fibrillation is converted successfully to sinus rhythm. On physical examination, there are no remarkable findings. Which of the following laboratory findings is most likely to be reported in this patient?

- (A) Increased urinary homovanillic acid (HVA) level
- (B) Decreased serum potassium level
- (C) Increased serum free T<sub>4</sub> level
- (D) Increased urinary free catecholamines
- (E) Decreased serum glucose level

8. A 72-year-old woman is admitted to the hospital in an obtunded condition. Her temperature is 37°C, pulse is 95/min, respirations are 22/min, and blood pressure is 90/60 mm Hg. She seems to be dehydrated and has poor skin turgor. Her serum glucose level is 872 mg/dL. Urinalysis shows 4+ glucosuria, but no ketones, protein, or blood. Which of the following factors is most important in the pathogenesis of this patient's condition?

- (A) HLA-DR3/HLA-DR4 genotype
- (B) Insulin resistance
- (C) Autoimmune insulinitis
- (D) Severe depletion of  $\beta$  cells in islets
- (E) Virus-induced injury to  $\beta$  cells in islets

9. A 39-year-old woman, G2, P2, whose last pregnancy was 14 years ago, has had regular menstrual cycles until 6 months ago, when the cycles ceased. She also reports expression of milk from her breasts. On physical examination, she is afebrile and normotensive. She is 150 cm (4 feet 11 inches) tall and weighs 63 kg (body mass index 28). Secondary sex characteristics are normal. Laboratory testing indicates that  $\beta$ -human chorionic gonadotropin level is normal. She has a normal growth hormone stimulation test. CT scan of the head shows no abnormalities of bone and no hemorrhage. Brain MRI shows fluid density within a normal-sized sella turcica. What is the most likely diagnosis?

- (A) Craniopharyngioma
- (B) Empty sella syndrome
- (C) Hereditary hemochromatosis
- (D) Prader-Willi syndrome
- (E) Prolactinoma
- (F) Sheehan syndrome

10. A 60-year-old woman has been feeling tired and sluggish for more than 1 year. On physical examination, her thyroid gland is not palpable; there are no other remarkable findings. Laboratory studies show a serum T4 level of 1.6  $\mu\text{g}/\text{dL}$  and a TSH level of 7.9 mU/L. Which of the following is most indicative of the pathogenesis of this patient's disease?

- (A) Irradiation of the neck during childhood
- (B) Antithyroid peroxidase antibodies
- (C) Prolonged iodine deficiency
- (D) Mutations in the RET proto-oncogene
- (E) Recent viral upper respiratory tract infection